MOVEMENT OF THE MENISCUS AND ITS ATTACHMENTS UNDER COMPRESSIVE LOADS

Maren Freutel[1], Andreas Seitz[1], Fabio Galbusera[1], Axel Bornstedt[2], Volker Rasche[2], Lutz Dürselen[1]

[1] *Institute of Orthopaedic Research and Biomechanics, University of Ulm, Ulm, Germany*

[2]*Department of Internal Medicine II, University Hospital of Ulm, Ulm, Germany*

Introduction

Magnetic resonance imaging (MRI) has been used in several studies [Vedi, 1999; Boxheimer, 2004; Tibesku, 2004; Fowlie, 2011] to investigate the movement of the meniscus. However, to our knowledge there is no study applying an objective evaluation method and investigating the three dimensional (3D) movement, also taking out-of-plane displacements into account. Therefore, the objective of this study was to determine the 3D displacement of the medial meniscus and its attachments under compressive loading with MRI and image registration.

Methods

A MRI compatible loading apparatus (Fig. 1) was placed in a 3T-MRI scanner (Achieva, Philips Medical Systems, Hamburg, Germany) and six porcine knee joints were scanned under unloaded and loaded (50% and 100% body weight (BW)) conditions. All images were acquired with standardized T1-weighted 3D TSE sequence. Acquisition parameters were: TE = 11.7 ms, TR = 750 ms, ETL = 5. Spatial resolution was 0.4x0.6x0.6 mm^3, pixel bandwidth 300 Hz, resulting in a scanning time of 60 minutes per scan. Before starting each scan the knee was loaded to the respective BW for 90 minutes to take account for the creep behavior of the soft tissues within the knee.



Figure 1: loading apparatus with femur fixture (1), knee coil (2), specimen (3), tibia fixture (4), rope to apply load (5), pneumatic cylinder (6)

The 3D displacement field of the meniscus was obtained using nonrigid registration. The centre of mass (COM) of five anatomical compartments (anterior horn, pars intermedia, posterior horn, anterior horn attachment, posterior horn attachment) was calculated and an ANOVA was conducted.

Results

The 3D movement of the meniscus and its attachments was apparent in the MRI sequences (Fig. 2). Increasing the load from 50% to 100% BW showed a statistically significant ($p < 0.01$) displacement. Loading the knee joint with 50% BW resulted in an overall movement of the COM of the meniscal compartments of 1.3 mm to 2.0 mm. The attachments moved by about 0.7 mm. During the second loading step (100% BW) the meniscal compartments moved by 2.1 mm to 2.6 mm and the attachments COM displaced in average by 1mm, which is about 50% less than the displacement of the meniscal compartments.

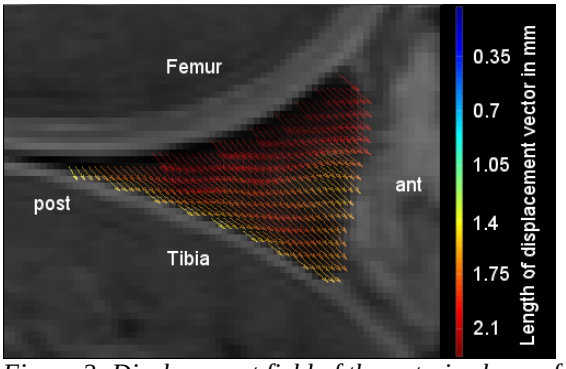

Figure 2: Displacement field of the anterior horn of the medial meniscus of one single MRI slice under 50% BW.

Discussion

The combination of MRI and image registration as a non-invasive approach to obtain the 3D displacement field of the meniscus and its attachments was used for the first time. In agreement with literature [Tibesku, 2004] the first loading step (50% BW) was more distinct than the second loading step (100% BW). For further studies (e.g. evaluating pathologies or embedding data into FE models) these values might be more valuable than previously obtained data, since the applied method is objective and respects all three spatial directions.

References

Boxheimer *et al.*, Invest Radiol, 39:254-263, 2004.
Fowlie *et al.*, Equine Vet J, 43:259-264, 2011.
Tibesku *et al.*, Sportverl Sportsch, 18:68-75, 2004.
Vedi *et al.*, Bone Joint Surg Br, 81:37-41, 1999.