CHARACTERIZATION OF MUSCLE DISPLACEMENT FIELD USING ULTRASOUND TECHNIQUE

Jean-Sébastien Affagard[1,2], Pierre Feissel[1], Sabine F. Bensamoun[2]
[1] *Laboratoire Roberval (UTC), UMR CNRS 7337, Compiègne, France*
[2] *BioMécanique et BioIngénierie (UTC), UMR CNRS 7338, Compiègne, France*

Introduction

The characterization of the muscle mechanical behavior with non invasive imaging technique is a current challenge. Elastography techniques allowed the clinician to assess the viscoelastic properties [Leclerc, 2012]. To further analyze the non linear characteristic of soft tissues, an algorithm based on the correlation of B-mode ultrasound signals was developed to measure the displacement field [Zhu, 2002]. This study aims at developing a method to measure the displacement field using a Digital Image Correlation (DIC) [Hild, 2006] from ultrasound acquisitions during a quasi-static loading.

Materials and methods

The thigh muscle was placed in a home-made compression device composed of two plates. The lower plate was only used as a support for the leg. The upper one can be moved down (along the Y axis) to compress the muscle and has a specific design to fit the ultrasound probe (9MHz). Moreover, sensors (Tekscan) were placed under the upper plate in order to quantify the distribution of pressure. Subsequently, two ultrasound (US) acquisitions were performed on uncompressed (Figure 1a) and compressed (Figure 1b) (1 kPa) quadriceps muscles of a healthy 33 year old male. These US images were acquired with parameters (frequency, gain, dynamic, etc...) set up as optimal to perform the DIC.

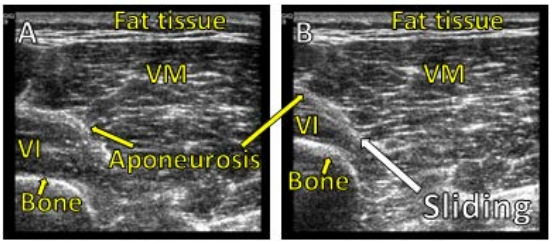

Figure 1: US images of a) uncompressed and b) compressed quadriceps composed of the Vastus Intermedius (VI) and the Vastus Medialis (VM)

The displacement field was then measured between the two recorded US images using the DIC method, based on the grey level comparison. Cartographies representing the horizontal (X) and vertical (Y) displacement fields (Figure 2) were obtained from the compressive mechanical test.

Results

The result of the US image acquired for the compressed muscle (Figure 1b) revealed a visual sliding of both vasti muscles around the aponeurosis.

Figure 2a showed the cartography of the displacement field measured along the Y axis. As expected, the lowest displacements (blue colour) were found around the bone while the highest displacements (red) were observed close to the fat tissue (about 10 mm).

Figure 2b illustrated the cartography of the displacement field measured along the X axis. A high displacement gradient from -5mm to 2mm (arrows) was observed around the aponeurosis located between the Vastus Intermedius (VI) and the Vastus Medialis (VM) muscles. Furthermore, this result confirmed the qualitative sliding obtained on the US image of the compressed muscle.

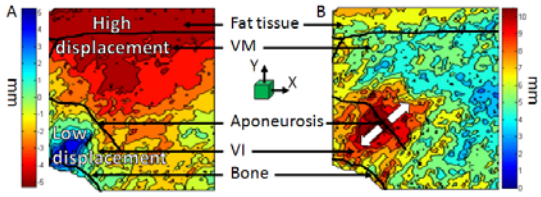

Figure 2: displacement field a) Y and b) X axis

Discussion

The use of DIC allows to improve the qualitative information of the US images with a quantitative displacement field. In perspective, this method will be used for the identification of the mechanical properties of the muscle.

References

Leclerc et al, J. Biomech, 45, 952–957, 2012.
Zhu et al, US Imaging, 24, 161–176, 2002.
Hild et al, Strain, 42(2), 69–80, 2006.

Acknowledgement

We thank GE. This project is co-financed by the European Union engaged in Picardy with the European Regional Development Fund and CNRS (grant Collegium UTC CNRS INSIS).